



**PATIENT**

Urban Berg

**SPECIES**

Canine

**BREED**

Miniture Aussie

**SEX**

Male

**AGE**

4.5 months

**WEIGHT**

15.7lbs

**INTERPRETED BY**

Maggie Machen Lamy,  
DVM, DACVIM  
(Cardiology)

**IMAGING PERFORMED BY**

Andy Carver, DVM

**HOSPITAL NAME**

Red River Animal  
Emergency Hospital  
and Referral Center

**REFERRING VET**

Dr. Carver

**INVOICE**

21562

**DATE**

10/18/21

**PRESENTING CLINICAL SIGNS**

History: Referred for grade 4/6 systolic murmur noted by primary vet at vaccine appt. Entirely asymptomatic as of now.

-Abnormal PE/Chem/CBC/UA Results: PCV/TS to screen for polycythemia after echo: 43%/ 7 Grade IV/VI systolic murmur loudest of left and right heart base, maybe very slight continuous component to murmur during diastole

**ECHOCARDIOGRAM FINDINGS**

2D, m-mode, color flow and doppler imaging is available. The mitral valve appears normal with no prolapse into the left atrial lumen. No mitral regurgitation. No left atrial enlargement. Normal LV diameter with adequate myocardial function. A relatively large ventricular septal defect is identified. VSD flow appears primarily left to right with high velocity flow (5.0m/s); however, a bidirectional component is certainly possible. The tricuspid valve appears normal with no tricuspid regurgitation. The right atrium is mildly enlarged and the right ventricular is moderate to severely enlarged with significant hypertrophy consistent with pressure overload. Subtle septal flattening. The pulmonic valve appears thickened with decreased excursion consistent with pulmonic stenosis. Pressure gradient is severely elevated. Significant post stenotic dilation. The aortic valve is suspected to be bicuspid with severe aortic insufficiency. The AI can be seen crossing the defect. Normal outflow velocities. The aortic root appears to be over-riding the IVS. No pericardial or pleural effusion noted. No obvious cardiac masses.

**CARDIAC CHART**

CANINE CARDIAC PARAMETERS	MR VMAX (m/s)	TR VMAX (m/s)	LA/AO (Boon method)	LA/AO (Heart Base; Swe)	FS (%)	EF (%)	EPSS (cm)
<b>NORMAL PARAMETER</b>	4.5-5.5	<2.7	1.3	<1.6	28-40	40-100	<0.6
<b>PATIENT</b>	NA	NA	NM	1.1	50	94	NM
CANINE CARDIAC PARAMETERS	HR (BPM)	AV VMAX (m/s)	PV MAX (m/s)	BODY WEIGHT (kg)	LA 2D short axis Base view (cm)	LVIDd Avg; 2D and m-mode short axis (cm)	LVIDs Avg; 2D and m-mode short axis (cm)
<b>NORMAL PARAMETER</b>	50-100	0.7-1.7	0.7-1.6	BELOW	BELOW	BELOW	BELOW
<b>PATIENT</b>	NM	1.6	4.9	7.1	1.5	2.5	1.2
*Normal chamber parameters expressed as a mean value (SD)				3	1.27 (5.3)	2.46 (2.46)	1.36 (5.5)
<b>BODY WEIGHT DEPENDENT PARAMETERS</b>				5	1.40 (4.5)	2.74 (5.2)	1.60 (4.7)
<i>*Note: All measurements based upon multi-modal images and methods. An average value is reported.</i>				10	1.50 (3.8)	3.27 (3.5)	2.06 (3.1)
				15	1.83 (2.0)	3.71 (2.4)	2.43 (2.1)
				20	2.02 (1.9)	4.14 (2.2)	2.80 (2.0)
				25	2.18 (2.4)	4.48 (2.9)	3.10 (2.5)
				30	2.33 (3.3)	4.83 (3.9)	3.39 (3.4)
				35	2.48 (4.3)	5.17 (5.0)	3.69 (4.5)
				40	2.62 (5.2)	5.48 (6.1)	3.96 (5.4)
				50	2.88 (7.1)	6.07 (8.3)	4.46 (7.4)

Adapted from June Boon, Veterinary Echocardiography, 1998  
Rishniw M and Hollis NE, J Vet Intern Med 2000; 14:429-435  
Hansson et al, Vet Rad and Ultrasound 2002  
Bonagura et al. Echocardiography: principles of interpretation, Vet Clin North Am 15:1177, 1995



**PATIENT**

Urban Berg

**SPECIES**

Canine

**BREED**

Miniture Aussie

**SEX**

Male

**AGE**

4.5 months

**WEIGHT**

15.7lbs

**INTERPRETED BY**

Maggie Machen Lamy,  
DVM, DACVIM  
(Cardiology)

**IMAGING PERFORMED BY**

Andy Carver, DVM

**HOSPITAL NAME**

Red River Animal  
Emergency Hospital  
and Referral Center

**REFERRING VET**

Dr. Carver

**INVOICE**

21562

**DATE**

10/18/21

**INTERPRETATION OF THE FINDINGS & FURTHER RECOMMENDATIONS**

Complex congenital heart disease is present, with both a VSD and significant pulmonic stenosis. This is likely a form of Tetralogy of Fallot (TOF) with an overlying aorta. The PS is primarily valvular; however, a dynamic sub or supra valvular component is not entirely ruled out. The VSD is mostly left to right; however, a bidirectional component is possible. Finally, the aortic valve is abnormal and suspected to be bicuspid with a severe aortic insufficiency. No additional congenital defects are observed; however, it is important to note that small changes are easily missed particularly given the abnormality of this cardiac exam.

**Given the complexity of the findings, consider referral to an attending Cardiologist in this case for advanced echocardiography and conformation of the diagnosis.** Surgical options can be discussed although long-term benefit is questionable in this case. If referral is declined, recommend institute medical management with Atenolol as pulmonic stenosis at least for now is the most significant issue (ie no significant LALV volume overload). This should not be instituted until at least 6 mo of age however, and only if referral is declined. No additional medications are clearly indicated at this time in this young puppy.

Assessment of progression in the future will help predict long term prognosis, which is guarded to poor going forward. There is a chance that the combination of right-sided issues may stable for some time; however, the patient will always be at risk for progression to right-sided CHF, symptoms of hypoxia, polycythemia, etc. Additionally, the severity of the aortic leak is concerning and may lead to LV volume overload going forward. Arrhythmias/collapse and/or sudden death is also a possibility. Hypoxic heart disease will often present as marked exercise intolerance, cyanosis and syncope at home.

Omega fatty acid supplementation and mild salt restriction may be of some long-term benefit. Lifelong activity restriction is advised. Elective anesthesia is not advised. If necessary, referral to a facility with an Anesthesiologist should be considered.

Monitor for development of a cough, labored breathing, abdominal distention, exercise intolerance or collapse episodes.

**PLAN**

Highly recommend referral. If declined and once the puppy is 6 months old, institute lose dose Atenolol 1-2mg/kg PO q24h (compounded liquid solution recommended). Up-titrate to effect; and target heart rate is <140bpm in hospital. A baseline BP and ECG are recommended q6-12mo.

Recommend conservative monitoring with a recheck echocardiogram in 6 months, sooner if any development of clinical signs.



**PATIENT**

Urban Berg

**SPECIES**

Canine

**BREED**

Miniture Aussie

**SEX**

Male

**AGE**

4.5 months

**WEIGHT**

15.7lbs

**INTERPRETED BY**

Maggie Machen Lamy,  
DVM, DACVIM  
(Cardiology)

**IMAGING  
PERFORMED BY**

Andy Carver, DVM

**HOSPITAL NAME**

Red River Animal  
Emergency Hospital  
and Referral Center

**REFERRING VET**

Dr. Carver

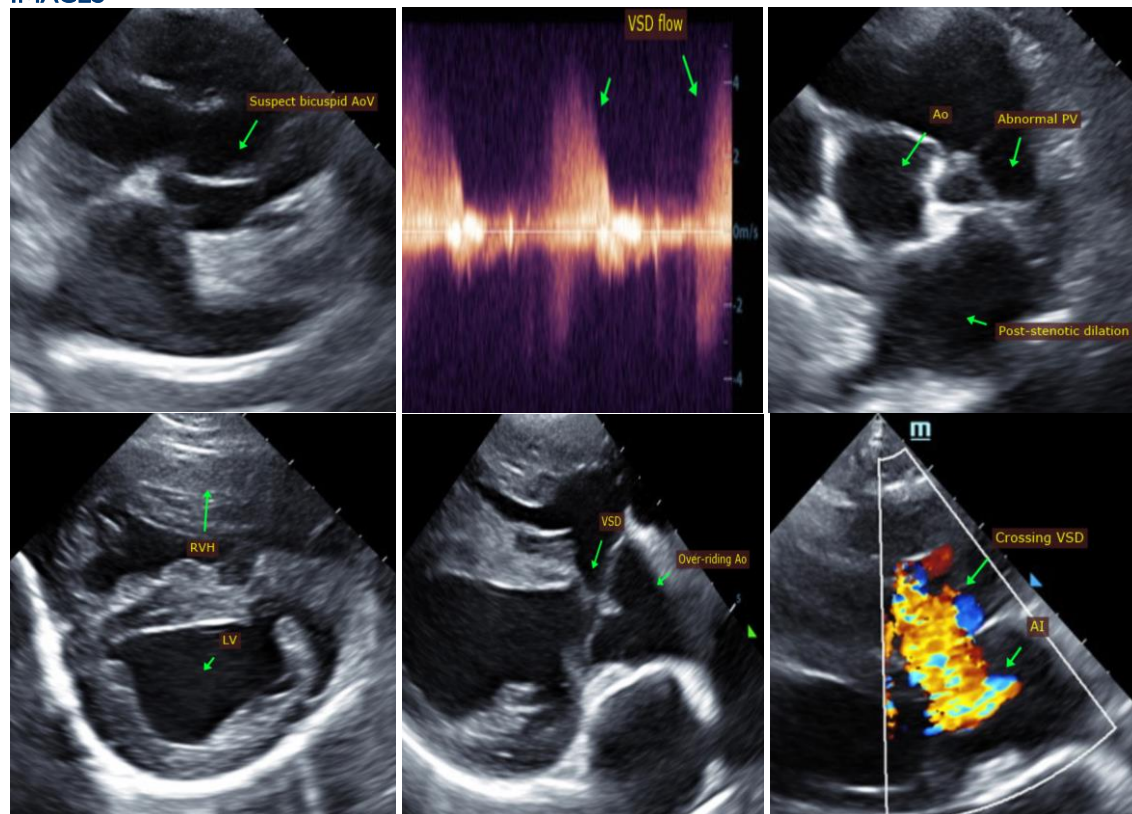
**INVOICE**

21562

**DATE**

10/18/21

**IMAGES**



The information and recommendations provided are based on the images presented by the referring veterinarian. No evaluation can be communicated regarding pathology that was not visible in the image/video clips provided.

Thank you for this referral. This report was generated using transcription software, and minor dictation errors may be present. If the clinical or image interpretation does not parallel your findings or if I can be of any further assistance, please contact me.

Maggie Machen Lamy, DVM  
Diplomate of the American College of Veterinary Internal Medicine (Cardiology)  
info@sonopath.com